IMAGING PERFORMED BY

IntraPet.com

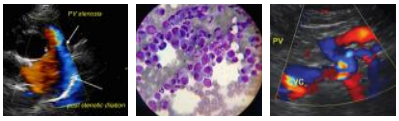

SonoPath
Clinical Sonography & Telecytology
EDUCATIONAL TELECONSULTATION SERVICES™
1-800-838-4268 info@sonopath.com SonoPath.com

PATIENT
Savannah Kahler

SPECIES
Feline

BREED
DSH

SEX
Female Spayed

AGE
6.24.07

WEIGHT
6.48lbs

INTERPRETED BY
Maggie Machen Lamy, DVM, DACVIM (Cardiology)

HOSPITAL NAME
Perry Hall Animal Hospital

REFERRING VET
Dr. Hatzigiannakis

INVOICE
29287

DATE
2.28.23

PRESENTING CLINICAL SIGNS

History: Weight loss, vomiting, behavior change. Intermittent soft stools. P has generalized muscle atrophy and a grade 3/6 systolic L parasternal systolic murmur
-Pertinent abnormal PE/Chem/CBC/UA Results: CBC wnl. fPL mildly increased. 3.9 ug/dL
Chem: BUN 43 (mild increase, ref 16-37 mg/dL) *note Creat 2.1 and SDMA 12 TP slightly decreased 5.7g/dL, Globulins slightly decreased 2.9 g/dL, ALT decreased 20 U/L, AST decreased 14 U/L
UA table top sample, usg 1.047, pH 5.5, prot 1+, ketone trace (neg glucose), epi 1+. T4 1.7. Fecal NSF
-Current medications: to start 2/18/23: cerenia 8mg PO SID, gabapentin 25mg PO TID, famotidien 5mg PO BID. Bland diet.
-Sedation used: Patient sedated with Torbugesic and Gabapentin.
-Pertinent previous ultrasound results: No previous.
-STAT: Not requested
-Imaging performed by: Andi Parkinson, BS, RDMS.

ECHOCARDIOGRAM FINDINGS

2D, m-mode, color flow and doppler imaging is available. The left ventricular wall is normal in dimension. There is a diffusely hyperechoic endocardium consistent with age-related fibrosis. Significant remodeling with regions of thinning and irregularity. The papillary muscles are hyperechoic. The left atrium is normal in size. The right atrium is normal in size. The right ventricle appears normal. The mitral valve is normal in structure and mobility. No MR. The tricuspid valve appears normal in structure and mobility. No TR. Blood flow through both the LVOT and RVOT are normal in velocity. No effusions. No obvious cardiac tumors.

CARDIAC CHART

FELINE CARDIAC PARAMETERS	BODY WEIGHT (kg)	HR (BPM)	IVSd (cm) (Moise, Pipers)	LVIDd (cm) (Moise, Pipers)	LVWd (cm) (Moise, Pipers)	FS (%)	EF (%)
NORMAL PARAMETER	------	150-240	3.5-0.55	<2 (mean 1.5)	3.5-0.55	35-67	80-100
PATIENT	2.9	165	0.46	1.3	0.48	56	89
FELINE CARDIAC PARAMETERS	**LA/AO** (Boon)	**LA/AO HEART BASE (Swe)** (Abbott)	**LA** 2D short axis Base view (cm) (Abbott)		**LVOT VEL** (m/s)	**RVOT VEL** (m/s)	**E max** (m/s)
NORMAL	<1.5	<1.3	<1.2		<1.6	<1.3	<0.9
PATIENT	NM	1.1	1.0		0.8	0.9	NM

Adapted from June Boon, Veterinary Echocardiography,1998
Abbott J & MacLean H JVIM 2006;20: 111-119, Moise et al. Am J Vet Res 47:1476, 1986. Pipers et al. Am J Vet Res 40:882, 1979.

INTERPRETATION OF THE FINDINGS & FURTHER RECOMMENDATIONS

Overtly normal geriatric cardiac structure and function. The LV is significantly remodeled, which is more than is typical and monitoring for progression is recommended. No significant valve leaks are noted, and flow through the great vessels is normal in velocity. No definitive cause is identified for the murmur in this study, making it likely physiologic in origin (i.e., secondary to tachycardia, volume changes, etc.). Given these findings and a normal LA dimension, no medications are indicated.

No cardiac contraindication for general anesthesia. Should fluid or steroid therapy be indicated in the future, any cat should be monitored for intolerance (changes in RR/RE).

Monitor at home for signs of cardiac compromise, including respiratory changes and/or signs of a blood clot event (paralysis, neurologic changes).

Recommend recheck echocardiogram in 1 year to assess for any progressive issues or development of disease the pre-existing murmur may mask.

IMAGES

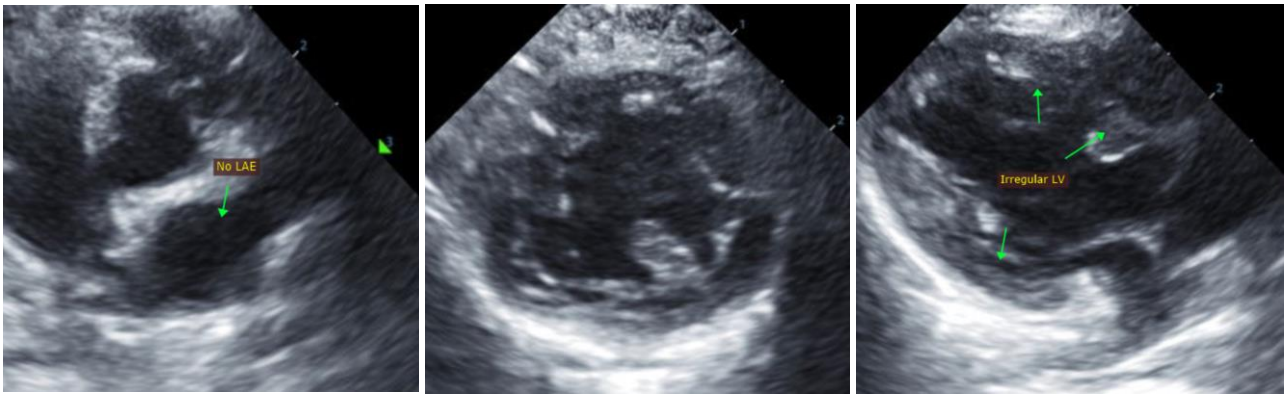

The information and recommendations provided are based on the images presented by the referring veterinarian. No evaluation can be communicated regarding pathology that was not visible in the image/video clips provided.

Thank you for this referral. This report was generated using transcription software, and minor dictation errors may be present. If the clinical or image interpretation does not parallel your findings or if I can be of any further assistance, please contact me.

Maggie Machen Lamy, DVM
Diplomate of the American College of Veterinary Internal Medicine (Cardiology)
info@sonopath.com